

**CLINICAL  
SECTION**

# Chrome cobalt mandibular advancement appliances for managing snoring and obstructive sleep apnea

**S. P. Ash and A. M. Smith**

Department of Orthodontics, Whipps Cross University Hospital, London, UK

Snoring and sleep apnea are chronic conditions. This article describes the use of cobalt chrome mandibular advancement appliances as a long-term, robust addition to the appliances used to treat these conditions. The clinical indications, appliance design, construction stages and special features of using cast alloy bases are described.

*Key words:* Sleep apnea, mandibular advancement

*Received 13th November 2003; accepted 12th February 2004*

## Background

Management of sleep-related breathing disorders is dependent upon an accurate diagnosis, within a multi-disciplinary setting.<sup>1</sup> Mandibular advancement appliances (MAA) are accepted as a possible method of managing patients with mild to moderate obstructive sleep apnea (OSA) or non-apneic snoring,<sup>2</sup> and high success rates have been reported in randomized controlled trials.<sup>3,4</sup> However, managing patients by nocturnal transitory mandibular advancement without surgically advancing the lower jaw, commits the patient to the wearing of an intra-oral appliance indefinitely, with regular reviews of the patient and appliance.

For this treatment modality, there is the need to provide robust, comfortable appliances that will be well tolerated by the patient. The appliance should distribute the occlusal loads and forces generated by the jaw protrusion, over the entire dental arch, whilst preventing unwanted eruption and orthodontic tooth movements. The absence of a restrictive fixed linkage between the arches is desirable. To improve patient acceptance, the appliance needs to have minimal bulk with minimal encroachment on the tongue space. The appliance should have the potential to be adjusted and modified to meet the changing clinical circumstances presented by the patient.

Several designs of MAA have been described based essentially on functional appliances.<sup>5</sup>

Most functional appliances have acrylic base plates that are active components and are subject to considerable forces often leading to appliance failure. To

overcome these shortfalls functional appliances are necessarily bulky, with a thick acrylic cross section, and have extensive hard and soft tissue coverage. The acrylic picks up stain and is difficult to keep clean. Repeated breakage of the acrylic or stainless steel wire components, especially where there is a fixed linkage between the parts, is a common drawback. Where a stainless steel shaft and piston fixed linkage mechanism is used, as in the removable Herbst appliance, fractures of the surrounding acrylic are a frequent problem. Snoring and OSA are chronic conditions and their management requires long-term solutions. If mandibular advancement appliances are to be used as a form of therapy, designs offering minimal maintenance are imperative.

This article reports on the design and application of chrome cobalt mandibular advancement appliances as a possible solution to these problems.

## Appliance design

Chrome cobalt oral prostheses have been used in prosthetic dentistry over many decades. They are recognized as being the gold standard for removable prosthetic oral appliances where a robust, well-tolerated long-term appliance is sought. Chrome cobalt appliances are noted for their dimensional stability, strength in thin cross-section and kindness to the oral tissues. In prosthodontic treatment planning, the chrome cobalt denture is chosen for its ability to direct the weight and forces of occlusion to the teeth, rather than the supporting soft tissues. In addition, the cast structure

incorporates both the supporting base and the retentive elements. Chrome cobalt is relatively inert, is easily cleaned and does not cause oral irritation. With careful planning other materials can, by physical keying, be attached to the chrome cobalt frame. These features are exploited in the chrome cobalt based mandibular advancement appliances.


## Clinical and laboratory stages

The same principles of prosthetic dentistry apply in the record taking and construction of the chrome cobalt base plates. Accurate working impressions are cast and special trays constructed. Where rapid access to a laboratory for casting impressions is available, alginate impressions will be adequate for the final working models. Alternatively, silicone or rubber-based impressions are taken and stone models cast.

The models are surveyed for construction of the chrome cobalt framework. The design will be dictated by individual patient circumstance. The following principles are applied. The chrome cobalt should aim to cover or engage as many teeth as possible. These may take the form of full cover or occlusal rests.

When surveying the model and designing the appliance, recognition of the path of insertion is important as it can be used as a means of enhancing appliance retention. In the mandibular appliance, the path of insertion should be in a vertical direction relative to the occlusal plane or have a slightly distal to mesial direction, so that forward protrusive forces will serve to increase appliance retention (Figure 1). Conversely, for the maxillary appliance, the path of insertion should be vertically directed or have a mesial to distal direction, relative to the occlusal plane (Figure 2). Clasps should be located on both the maxillary and mandibular appliances on both sides of the mouth. The mandibular clasps should be designed to approach from the mesial into undercuts on the distal aspects of the lower premolar and molar teeth. In the maxillary appliance, the clasps should approach from the distal into the mesial undercuts of the upper canine/premolar region (Figure 3). Additional clasps or incisal rests can be placed on the anterior teeth. Clasps placed on the lower molars and in the upper canine/premolar region allow, where necessary, the placement of Class II or vertically stabilizing traction, to reinforce the forward jaw posturing and vertically directed traction to prevent the mandible opening and the jaw hinging backwards (Figure 4).

The chrome cobalt skeleton is constructed of a mesh and slightly raised over the occlusal surfaces in the buccal segments (Figure 5). This allows heat-cured



**Figure 1** A lower working model being surveyed for undercuts and path of insertion

acrylic to flow beneath the chrome cobalt mesh and achieve a positive attachment of acrylic to chrome cobalt. The design of the transpalatal or lingual elements will be dictated by the clinical situation. Generally, a skeleton design is preferred to minimize appliance size and reduce intrusion into the tongue space (Figure 6).

The cast and finished chrome cobalt skeleton is returned to the clinic and tried in the patient's mouth. Any problems with fitting of the chrome cobalt base plates should be identified at this stage, and if necessary new impressions and a remake of the chrome cobalt base plates may be indicated.

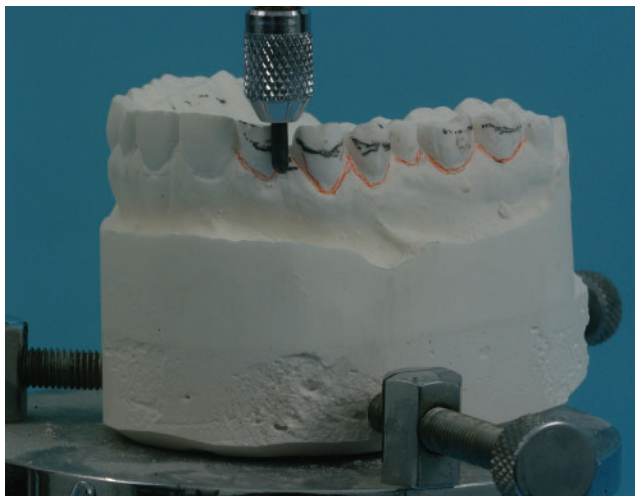A forward postured jaw registration, as for a functional appliance, is taken. Maximum comfortable protrusion has been shown to provide the greatest pharyngeal opening.<sup>6</sup> However, at least 75% maximum protrusion and more than 5 mm advancement is recommended.<sup>7</sup> Minimal vertical opening is advised to limit any downwards and backwards rotation of the mandible. The working models are mounted on an articulator and acrylic wedges are placed on the chrome cobalt base plates, ensuring that the acrylic encapsulates the chrome cobalt mesh in the buccal segments. The appliance is then invested and the acrylic heat cured.

## Clinical findings

The appliances are well tolerated by patients and in our experience they are certainly preferred to the

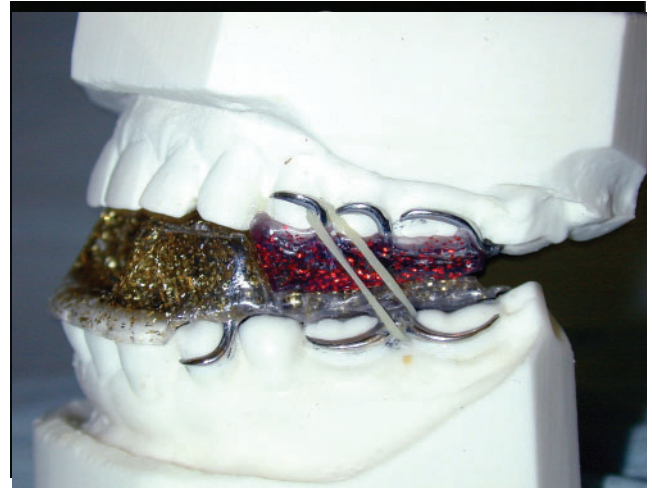

(a)



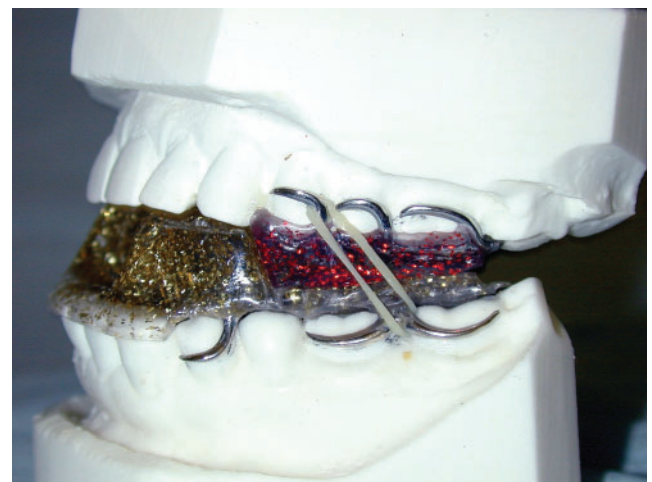(b)

**Figure 2** An upper working model being surveyed to identify undercuts and establish a path of insertion

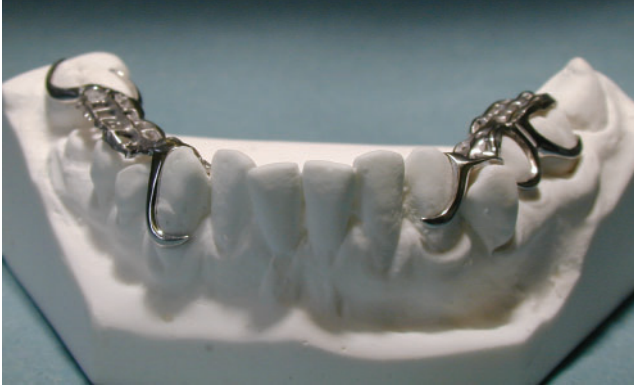

**Figure 3** An upper chrome cobalt skeleton showing mesially approaching clasps on the upper cuspid teeth, occlusal cover and rests in the buccal segments

conventional acrylic/stainless MAA previously used. During 26 months of use and 36 patients treated, no appliance breakages were reported. To a limited extent, the heat-cured acrylic can be adjusted without the need to alter the chrome cobalt base plates. In situations where vertical bite opening needs to be kept to a minimum, the height of the lower bite blocks can be maintained by extending the acrylic blocks into the palatal area as viewed from the lingual aspect in (Figure 7). This modification acts as a further means of maintaining a forward postured jaw without excessive vertical opening of the mouth (Ben Stark, personal communication).



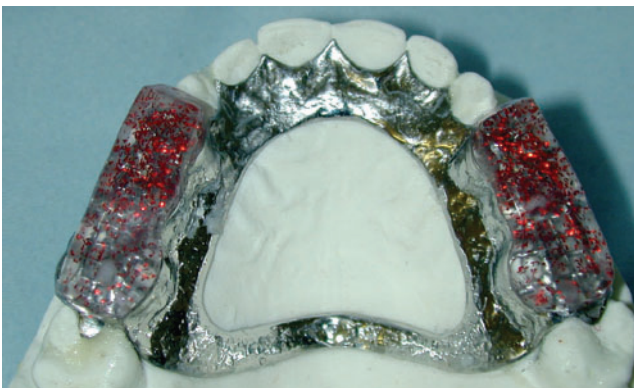**Figure 4** Completed chrome cobalt mandibular advancement appliance showing class two elastics to reinforce forward posturing and jaw closure



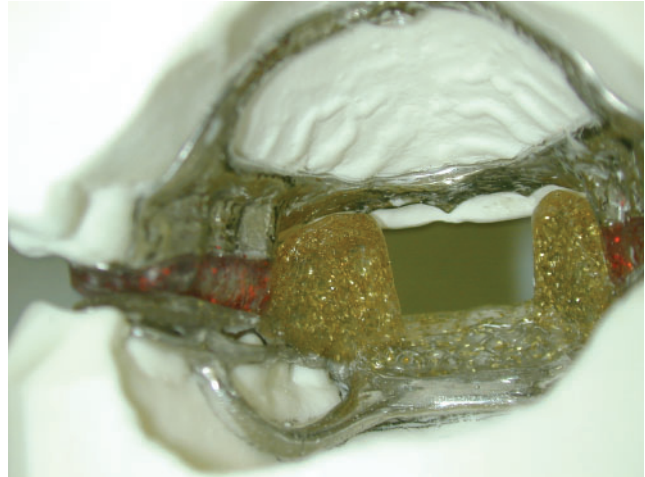
**Figure 5** The chrome skeleton meshwork is kept clear of the occlusal surfaces to allow acrylic flow and keying

## Discussion

The use of chrome cobalt-based mandibular advancement appliances may provide an alternative in the appliance armamentarium for managing snoring and OSA. The established benefits of chrome cobalt in prosthodontic dentistry are readily transferred to this application. Features of cast metal may be used to enhance retention, stability and patient acceptance. Chrome cobalt is generally thought to be kinder to the mucosal tissues than acrylic when *in situ* for a prolonged time. Its strength in thin sections allows the construction of less bulky appliances, which may be preferred by patients. The possible disadvantages of this approach are the financial cost, dependence on a chrome cobalt casting laboratory, and the additional clinical and laboratory stages. However, these disadvantages may be outweighed by the possible benefits of patient tolerance and appliance durability. Patients once accustomed to their appliances may avoid the inconvenience



**Figure 6** Completed maxillary chrome skeleton. The colour helps patient identification



**Figure 7** A lingual view of the lower appliance showing extension of the lower bite blocks into the palatal vault

of having to re-adapt to their replaced fractured acrylic and stainless steel-based appliances. Unfortunately, if the patient experiences tooth loss or further dental disease, as with any cast prosthesis, the appliance may no longer fit, and a complete remake of one or both parts of the appliance may be indicated.

Whilst there are promising clinical observations, the approach should be subject to prospective randomized controlled trials comparing this appliance with conventional mandibular advancement appliances.

## Acknowledgements

Our grateful thanks are given to Mr D. Solomon & Ms S. Owen for their technical support.

## References

1. L'Estrange PR, Battagel JM, Nolan PJ, Harkness B, Jorgensen GI. The importance of a multidisciplinary approach to the assessment of patients with obstructive sleep apnoea. *J Oral Rehab* 1996; **23**: 72–7.
2. American Sleep Disorders Association Report. Practice parameters for the treatment of snoring and obstructive sleep apnea with oral appliances. *Sleep* 1995; **18**: 511–13.
3. Clark GT, Blumenfeld I, Yoffe N, Peled E, Lavie P. A crossover study to compare the efficacy of continuous positive airway pressure with anterior mandibular positioning devices on patients with obstructive sleep apnea. *Chest* 1996; **109**: 1477–83.
4. Mehta A, Qian J, Petocz P, Ali Darendeliler M, Cistulli PA. A randomized controlled study of a mandibular advancement

- splint for obstructive sleep apnea. *Am J Respir Crit Care Med* 2001; **163**: 1457–61.
5. Schmidt-Nowara WW, Lowe AA, Wiegand L, Cartwright R, Perez-Guerra F, Menn S. Oral appliances for the treatment of snoring and obstructive sleep apnoea: A review. *Sleep* 1995; **18**: 501–10.
  6. Ferguson KA, Love LL, Ryan F. Effect of mandibular and tongue protrusion on upper airway size during wakefulness. *Am J Respir Crit Care Med* 1997; **155**: 1748–54.
  7. Millman RP, Rosenberg CL, Kramer NR. Oral appliances in the treatment of snoring and sleep apnea. *Clin Chest Med* 1998; **19**: 69–75.